



Effects of a Novel Non-Biologic Desiccant to Remove Bacteria Using a Deep Dermal Wound Porcine Model

Stephen C. Davis¹, Jie Li¹, Tongyu Cao Wikramanayake¹, Joel Gil¹, Alexander Higa¹, Michael Solis¹ and Steven Kavros²

¹Dr. Phillip Frost Department of Dermatology and Cutaneous Surgery, Miller School of Medicine, University of Miami, Florida, ²EPIEN Medical, Inc., St. Paul, MN, Vascular Surgery Associates, Blaine, MN.



Abstract:

Nosocomial infections are common in many healthcare provider settings. Debridement plays a critical role in wound bed preparation and management. In addition to removing necrotic tissue, debridement can eliminate bacteria that are frequently harbored within the tissue.¹ Infected wounds particularly with drug-resistant bacteria such as *Staphylococcus aureus* and *Pseudomonas aeruginosa* have a high-risk of impeding the healing process. The purpose of this study was to examine the ability of a novel debridement method which uses a novel molecular cleaning technology, to remove both necrotic tissue and bacteria from infected wounds using a porcine wound model. 2,3 One hundred and twenty deep dermal wounds (22mmx22mmx3mm) were created and inoculated with either Methicillin Resistant *Staphylococcus aureus* (MRSA USA300) or *Pseudomonas aeruginosa* PA09-010 (military isolation). Wounds were covered for 72 hours to allow biofilm formation. Baseline wounds (3) were assessed prior treatment application and remaining wounds were assigned to one of three treatment groups: 1) Regenerative Debridement Technology [RDT*], 2) Gauze with sterile saline, or 3) Untreated control. All wounds were treated for 30 seconds and then rinsed with 10ml of sterile saline. After treatment application a sterile gauze was used to remove the slough and wounds were covered with a polyurethane film. Amount of slough was assessed using digital planimetry. Biopsies were taken on days 4, 8 and 11 post-treatment for microbiology, histological and molecular (rt-PCR) assessments. After initial treatment, over 80% more slough was removed with RDT as compared to controls.. RDT also achieved MRSA USA300 bacterial reductions of more than 99.70% and 99.86% when compared to baseline bacterial counts and untreated group in all assessment days, respectively. However, wounds infected with PA09-010 resulted in lower reductions compared to Untreated control and baseline wounds, reaching the higher percentage of reduction by day 11 with more than 98.3%. RDT treated wounds resulted in higher reductions in wounds infected with MRSA USA 300 than infected with PA09-010 when compared to Gauze with sterile saline group in assessment Days 4, 8 and 11. RDT treated wounds showed a more than 1 Log CFU/g bacterial reduction compared day 11 to day 4 for both microorganism treated. An initial increase in epithelialization was noted with RDT on day 4 compared to other treatment groups. Molecular results showed on Day 8 around 62% of reduction in IL-1 α expression in wounds treated with RDT compared with Gauze with sterile saline. Levels of TNF α were increased on day 4 with RDT treatment in then became reduced on Days 8 and 11, as compared with baseline wounds. MMP-9 was also found to reduced on day 4 as compared to control wounds. Overall, the RDT appeared to be the most effective treatment group to reduce MRSA counts compare to wounds infected with PA09-010. These results may have significant clinical implications when treating patients with acute or chronic wounds..

*Revity – Epien Medical, St. Paul, MN

Introduction:

The presence of biofilms in wounds can be an important barrier to effective treatments.^{4,5} Many patients in hospitals acquire nosocomial infections that become a challenge to prevent and treat⁶. Such infections are often caused by antibiotic-resistant organisms such as Methicillin Resistant *Staphylococcus aureus* (MRSA) and *Pseudomonas aeruginosa*. An additional challenge when attempting to halt bioburden proliferation is the microorganism's ability to colonize a surface by forming a protective biofilm matrix.⁷ MRSA forming extracellular polymeric substance (EPS) makes treatment more difficult to manage. Debridement techniques have shown limited ability to mechanically remove bacteria from a wound bed.¹ RDT* is a topical formulation that can be used by healthcare practitioners for wound cleansing. The purpose of this study was to evaluate the ability of RDT* to remove non-viable tissue in wound debridement and also examine its ability to reduce the bacterial load in wounds inoculated with methicillin-resistant *Staphylococcus aureus* (MRSA) and *Pseudomonas aeruginosa*.

References

1. Nisbaum AG, Gil J, Rippy MK, Wayne B, Valdes J, Claro A, Davis SC. Effective Method to Remove Wound Bacteria: Comparison of Various Debridement Modalities in an In Vivo Porcine Model. J Surg Res. 2012; 176(2):701-7.
2. Davis SC, Gil J, Solis M, Higa A, Mills A, Simms C, Valencia-Pena P, Li J, Raut V. Antimicrobial Effectiveness of Wound Matrices containing Native Extra Cellular Matrix (ECM) with Polyhexamethylene Biguanide (PHMB), Int Wound J. 2021;1-14. DOI: 10.1111/wj.13600.
3. Davis SC, Gil J, Li J, Simms C, Valdes J, Solis M, Higa A. Effect of Mechanical Debridement, and Irrigation with Hypochlorous Acid Wound Management Solution on Methicillin-resistant Staphylococcus aureus Contamination and Healing Deep Dermal Wounds in a Porcine Model. Wound Management Prevention. 2021 Aug;67(8):24-31. PMID: 34370678.
4. Davis SC, Martinez L, Kirsner R. The diabetic foot: the importance of biofilms and wound bed preparation. Current Diabetes Reports. 2006 Dec;6:439-45.
5. Davis SC, Ricotti C, Cazzaniga AL, Welch E, and Mertz PM. Microscopic and Physiological Evidence for Biofilm-Associated Wound Colonization in-vivo. Wound Repair and Regeneration. 2008; 16: 23-29
6. Monogro AF, Muppidi V, Regunath H. Hospital Acquired Infections. 2021 Aug 30. In: StatPearls [Internet]. Treasure Island (FL): StatPearls Publishing; 2022. Jan-. PMID: 28722887.
7. Davis K, Bills J, Barker J, Kim P and Lavery L. Simultaneous irrigation and negative pressure wound therapy enhances wound healing and reduces wound bioburden in a porcine model. Wound Repair Regen. 2013 Nov-Dec; 21(6): 869-75.
8. Sullivan TP, Eaglstein WH, Davis SC, Mertz P. The pig as a model for human wound healing. Wound Repair Regen. 2001

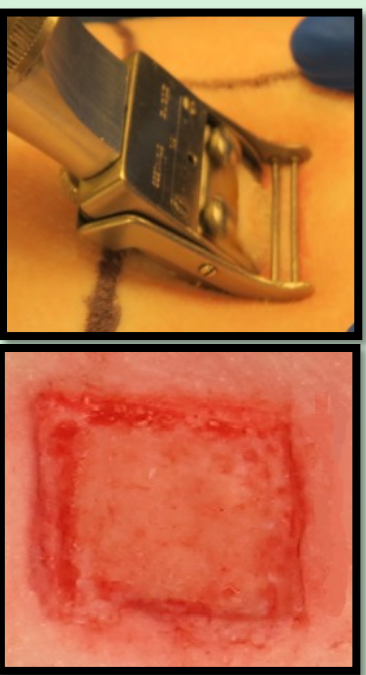
Materials and Methods:

1. Experimental Animals:

Swine were used as our experimental animal due to the morphological, physiological, and biochemical similarities between porcine skin and human skin.⁸

2. Wounding Technique:

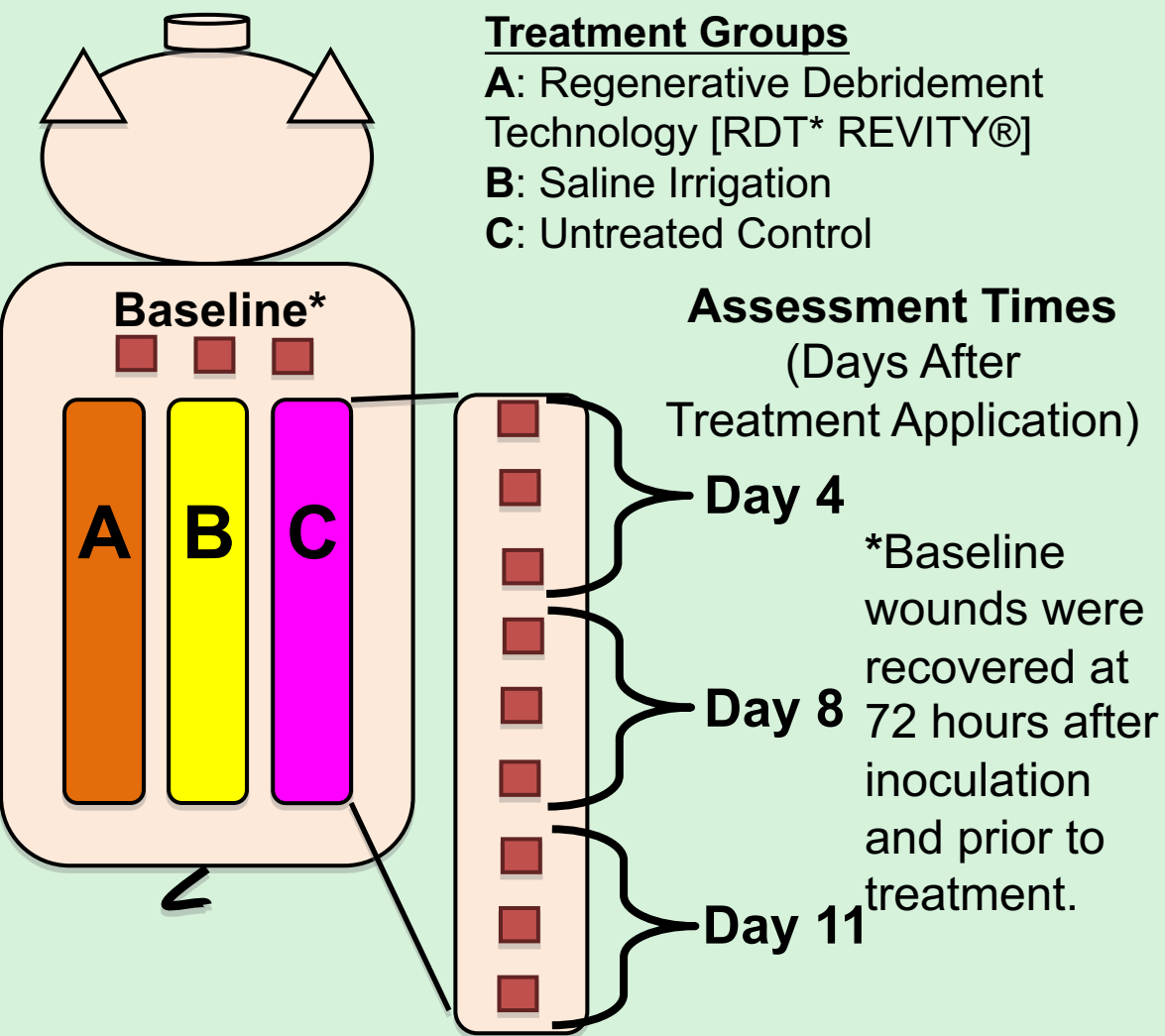
A specialized electrokeratome was used to create thirty (30) deep reticular dermal wounds measured (22mm x 22mm x 3mm deep) on the paravertebral and thoracic area.



3. Inoculation:

- After creation of wounds, 25 μ l of Methicillin Resistant *Staphylococcus aureus* (MRSA USA300) or *Pseudomonas aeruginosa* was used to inoculate each wound by scrubbing 10⁶ CFU/ml inoculums into each wound with a teflon spatula (30 seconds).
- Nine (9) wounds were assigned to each treatment group (3 groups total) and 3 wounds were used as a baseline
- All wounds were then covered with a polyurethane film for 72 hours (to allow biofilm formation).

4. Experimental Design:



5. Treatment Regimen:

- After 72 hours, all wounds were debrided.
- Wounds treated with RDT received 500 μ l.
- RDT treatment was spread with spatula and allowed to stay in place for 30 seconds
- Saline Irrigation wounds each had a premoisten gauze (500 μ L of sterile saline) placed over the wound which was allowed to stay in place for 30 seconds.
- After 30 seconds, all wounds were rinsed with a 10mL syringe of sterile saline (image showed rinsing after RDT application).
- After rinse wounds were gently wipe with moistened sterile PBS gauze and then covered with Tegaderm.

6. Wound Recovery:

Microbiology Analysis:

- Baseline wounds were recovered before treatment application. On days 4, 8 and 11 post treatment, three wounds per group were recovered by using a 6mm punch biopsy (photo g).
- Biopsies were homogenized and combined with a scrub solution.
- Serial dilutions were made (photo h) and quantified using the Spiral Plater System (which deposits a defined amount (50 μ l) of suspension over the surface of a rotating agar plate: photo i) MRSA USA300 was isolated on ORSAB (Oxacillin Resistance Screening Agar Base) incubated at 37 \pm 2 $^{\circ}$ C for 36-48 hours (photo j). The colony forming units per g (CFU/g) were calculated.

Histology Analysis:

- From the same wound incisional biopsies were also taken. Incisional biopsy was obtained through the center of the wounds including normal adjacent skin on both sides (photo g).
- The specimens were evaluated blinded via light microscopy and examined for the following elements: Percent of wound epithelialized (%), Epithelial thickness (cell layers μ m), White cell infiltrate. Mean Score: 1 = absent, 2 = mild, 3 = moderate, 4 = marked, 5 = exuberant, Granulation Tissue Formation. 0 = 0, 0.5 = 1-10%, 1 = 11-30%, 2 = 31-50%, 3 = 51-70%, 4 = 71-90%, 5= 91-100% and New Blood Vessel Formation: Presence of new blood vessels (non-quantitative). Mean Score: 1 = absent, 2 = mild, 3 = moderate, 4 = marked, 5 = exuberant.

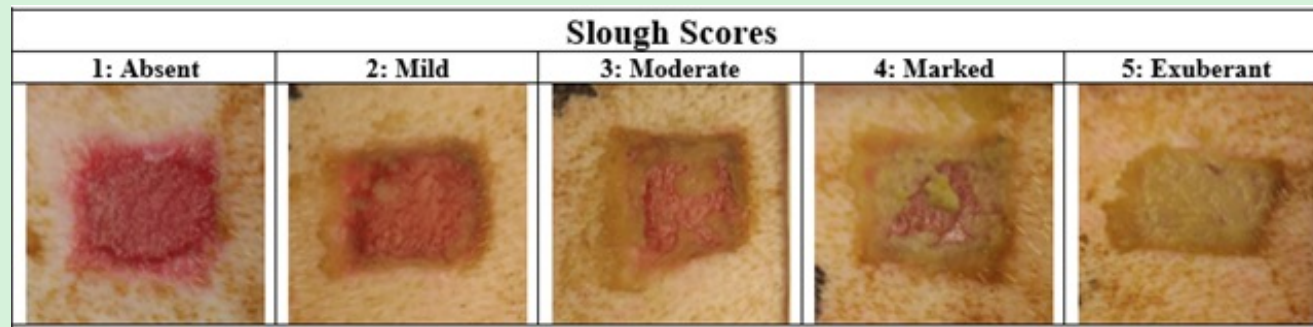Molecular Analysis:

- From the same wound only for the animal infected with MRSA a 4mm pouch biopsy was taken to analysis iL-1 α , TNF α and MMP-9

Clinical


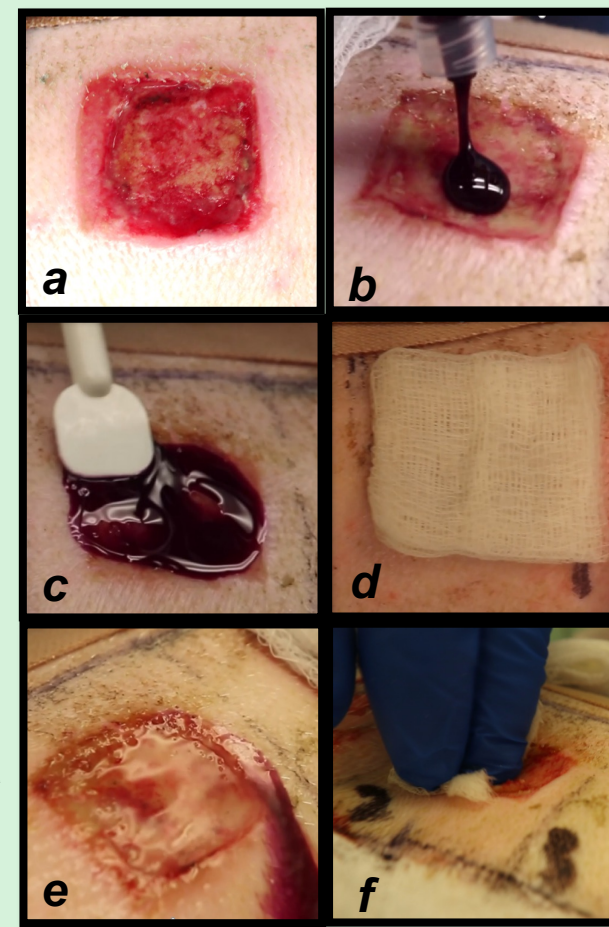
Observations:

- The amount of slough and was score using the scales below.

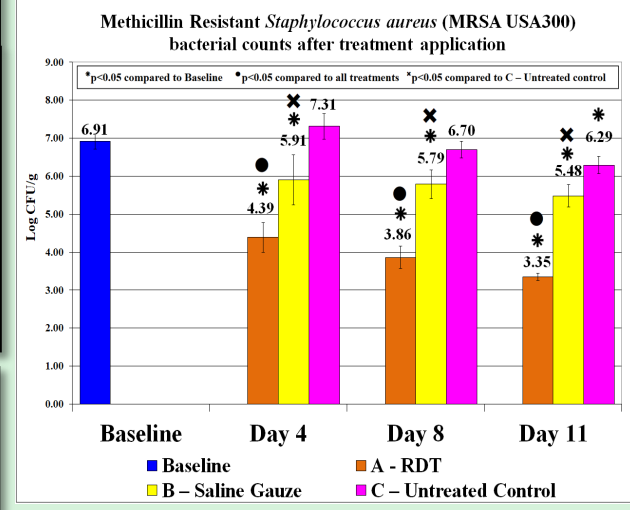
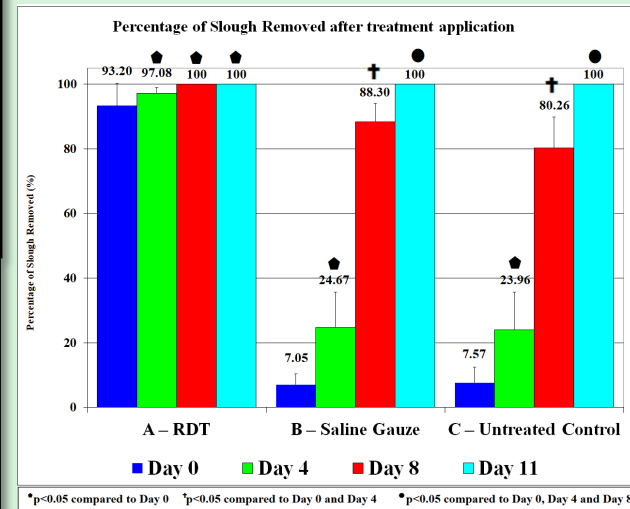


Digital Photography & Measurement of the Slough:

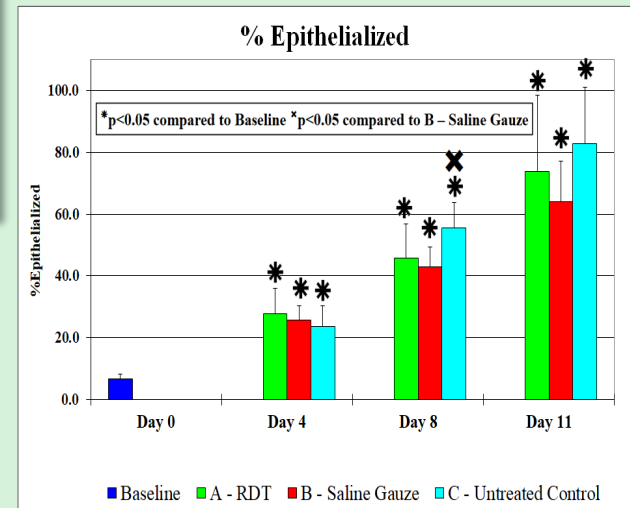
- Photographs was taken before and after treatment by using two rulers that was placed tangential. The wound area that includes slough was traced by digital imaging with ImageJ.



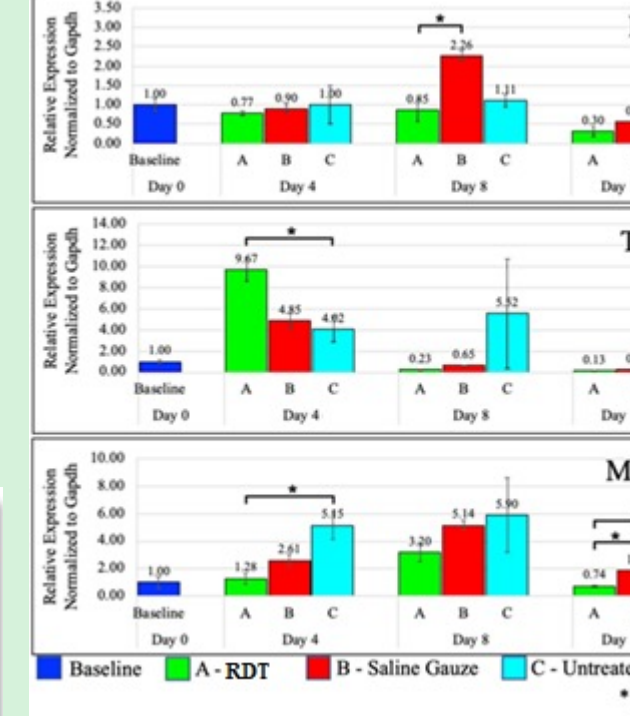
Methicillin Resistant Staphylococcus aureus (MRSA USA300)



- RDT treated wounds resulted in reductions of 96.97%, 98.81% and 99.25% when compared to Gauze with sterile saline group in assessment Days 4, 8 and 11, respectively (p<0.05). RDT treated wounds showed a more than 1 Log CFU/g bacterial reduction compared day 11 to day 4.



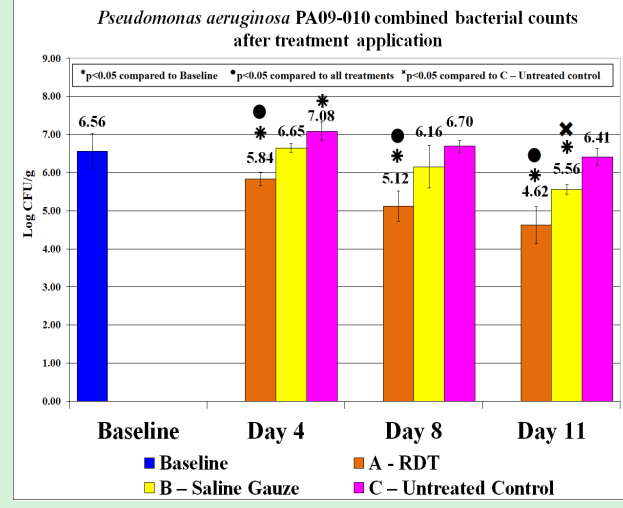
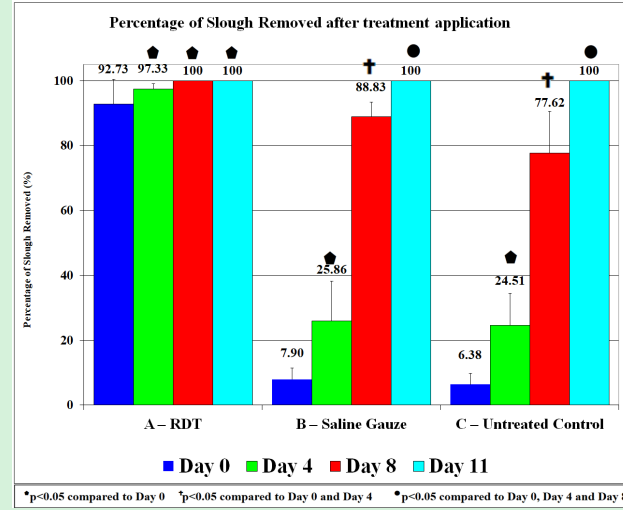
- On days 8 and 11, wounds treated with RDT results in 45.8 and 73.7% of re-epithelialization. RDT showed p<0.05 compared to baseline. All other parameters had similar results.



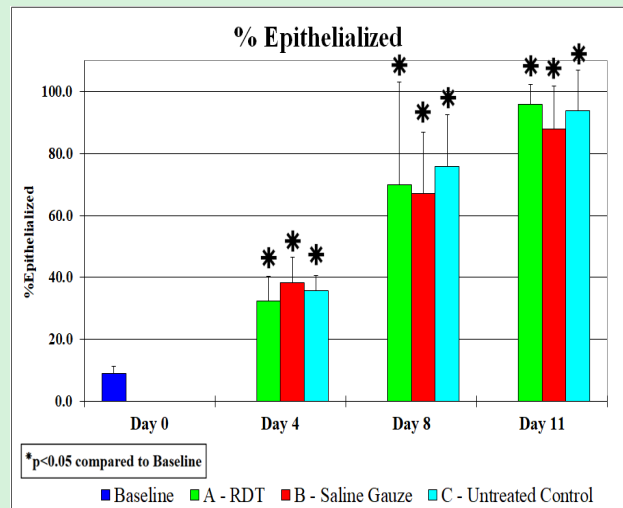
Contact Information: Stephen C. Davis / Research Professor
Dr. Phillip Frost Department of Dermatology and Cutaneous Surgery.
Miller School of Medicine, University of Miami
sdavis@med.miami.edu. Ph: 305.243.4897

Results:

Pseudomonas aeruginosa PA09-010



- RDT treated wounds resulted in reductions of 96.97%, 98.81% and 99.25% when compared to Gauze with sterile saline group in assessment Days 4, 8 and 11, respectively (p<0.05). RDT treated wounds showed a more than 1 Log CFU/g bacterial reduction compared day 11 to day 4.



- On days 4 and 8, wounds treated with RDT results in 32.2 and 69.9% of re-epithelialization. RDT showed p<0.05 compared to baseline. All other parameters had similar results.

- By day 8 after treatment, there was a 62% reduction in IL-1 α expression level in RDT versus Saline (p<0.05). On day 4 TNF α levels were significantly higher in RDT treated versus untreated samples (p<0.05). Expression of MMP-1 and MMP-9 was increased in all the samples with or without RDT treatment, with untreated samples showing the most robust increase. MMP-9 expression levels in the RDT-treated samples were closest to baseline and were significantly lower than Saline Gauze treated or untreated samples

Conclusions

- Wounds treated with RDT had a higher percentage of slough removal and MRSA or PA reduction. REVITY® treated wounds had a desirable effect on slough removal the day of treatment (day 0) and 4 days after this single application the count reached a higher bacterial reduction compared with the baseline and untreated wounds. Further analysis against a Positive Control group, such as Mupirocin, SSD and/or other conventional antimicrobial/healing therapies, would provide more insight on Revity's effectiveness to compete against what is currently utilized in wound care settings.