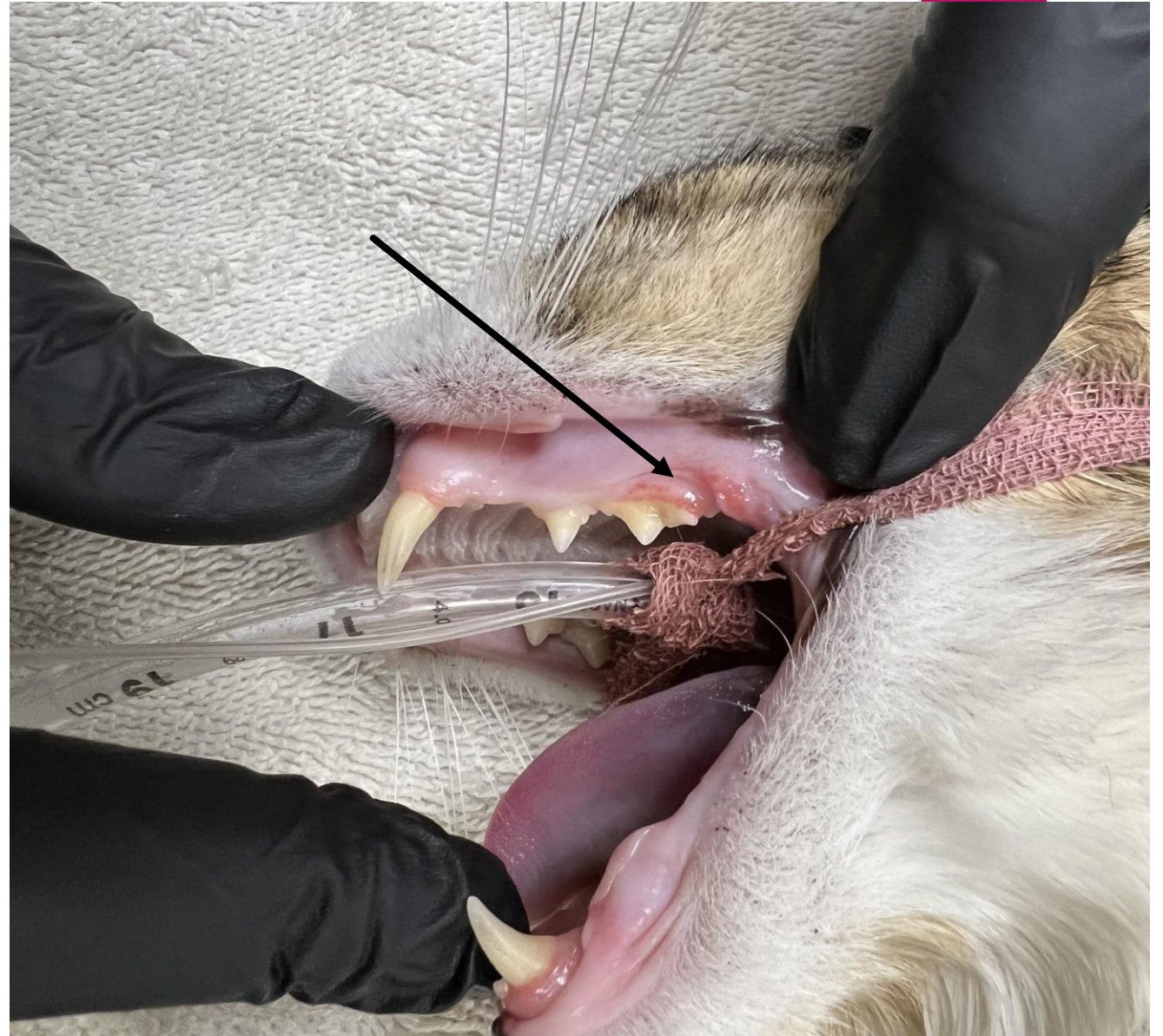

# MILD FELINE STOMATITIS

DAVID NIELSEN, DVM

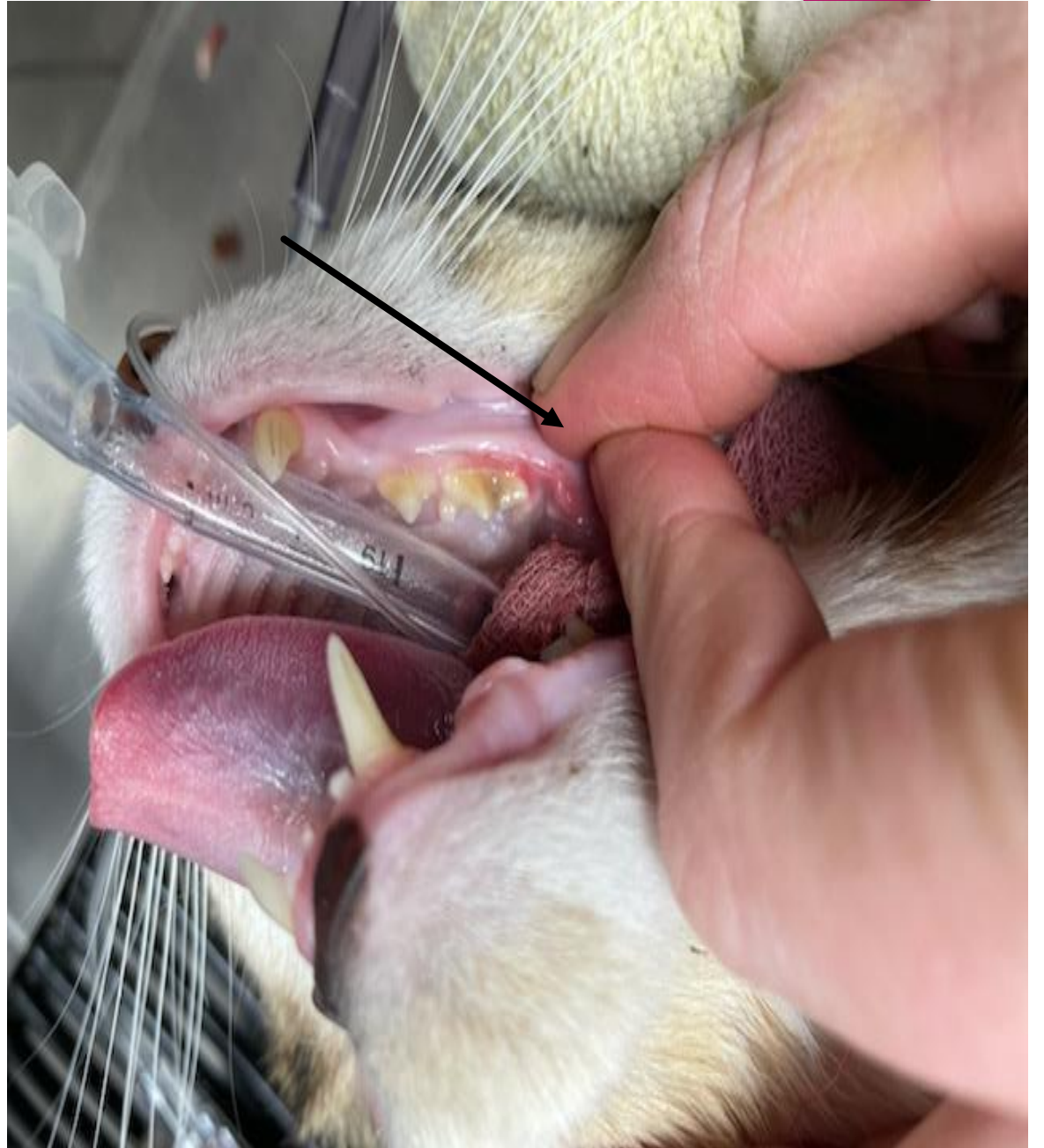## MILD FELINE STOMATITIS

- Biddie is a 6-year-old neutered male with prior treatment of feline stomatitis
- He has an inflamed mucosal lesion on the posterior mandible
- There is inflammation and swollen mucosa associated with the lesion
- Painful when he closes his mouth when the lesion is contacted
- The pain alters his behavior which leads to fighting with the other cats and spraying in the house



## MILD FELINE STOMATITIS

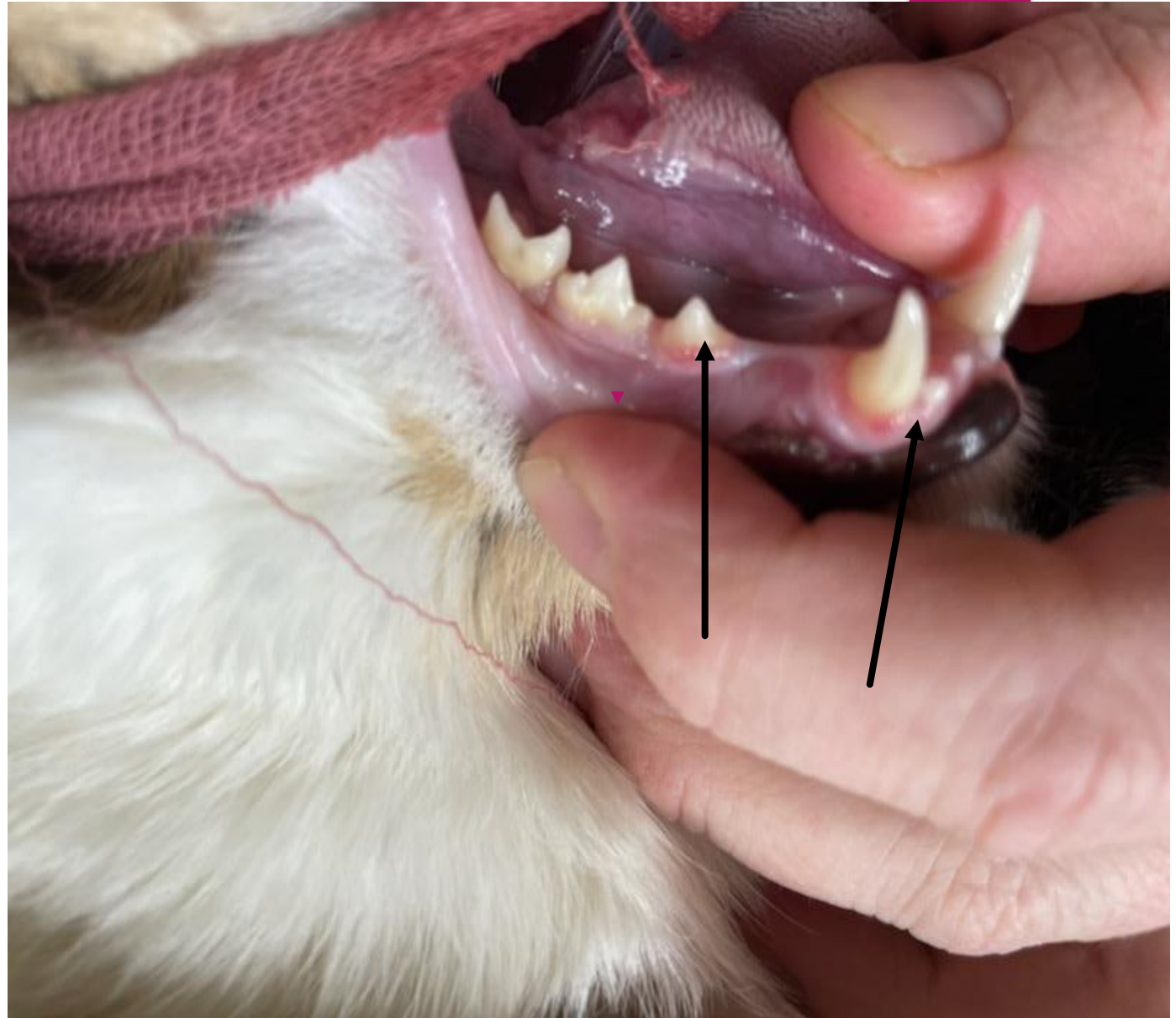
- Pre-prophylaxis
- Note the inflammatory gingival lesions





## MILD FELINE STOMATITIS

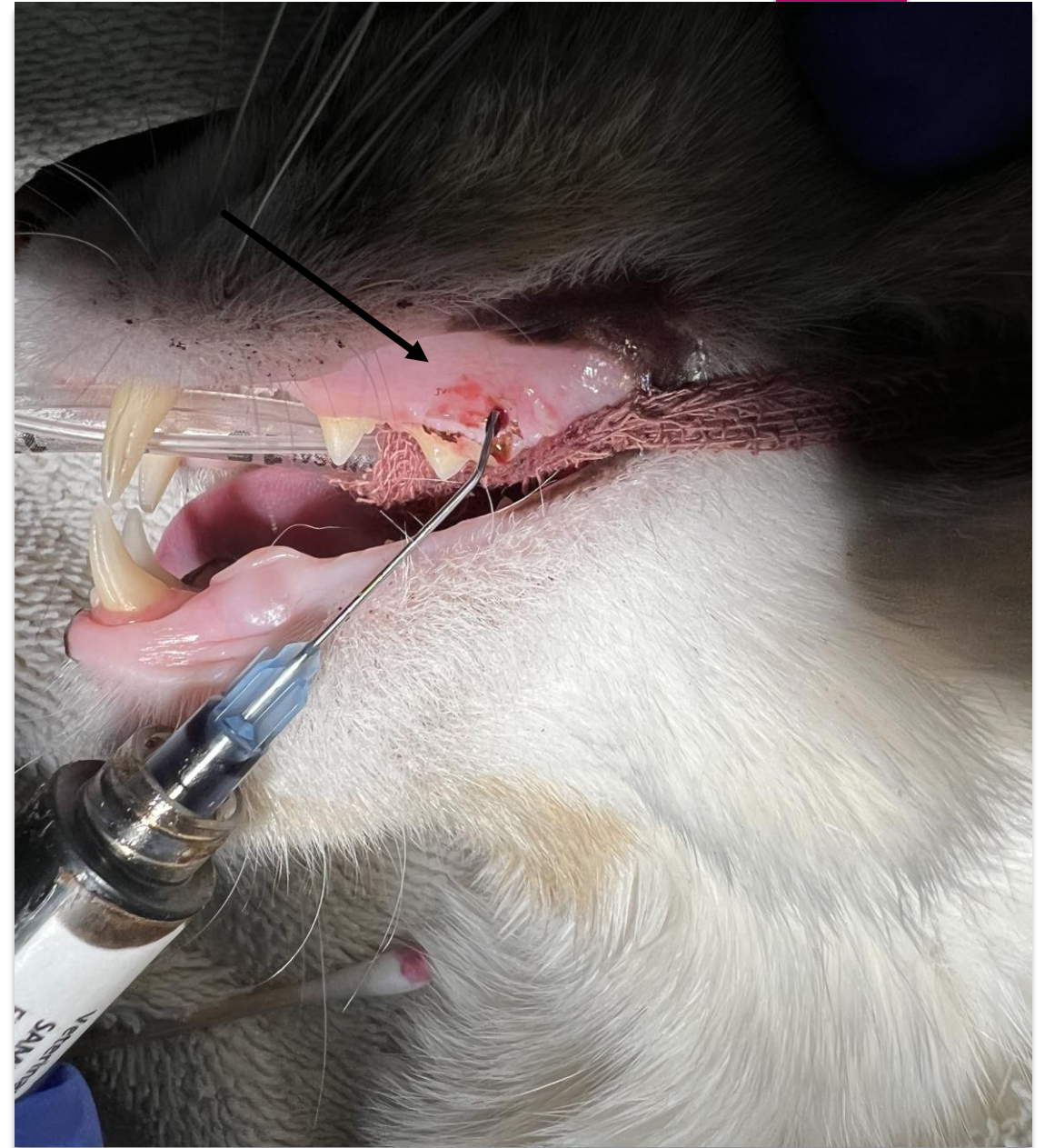- Lower right mandible
- Multiple gingival lesions



## MILD FELINE STOMATITIS

### FELINE STOMATITIS

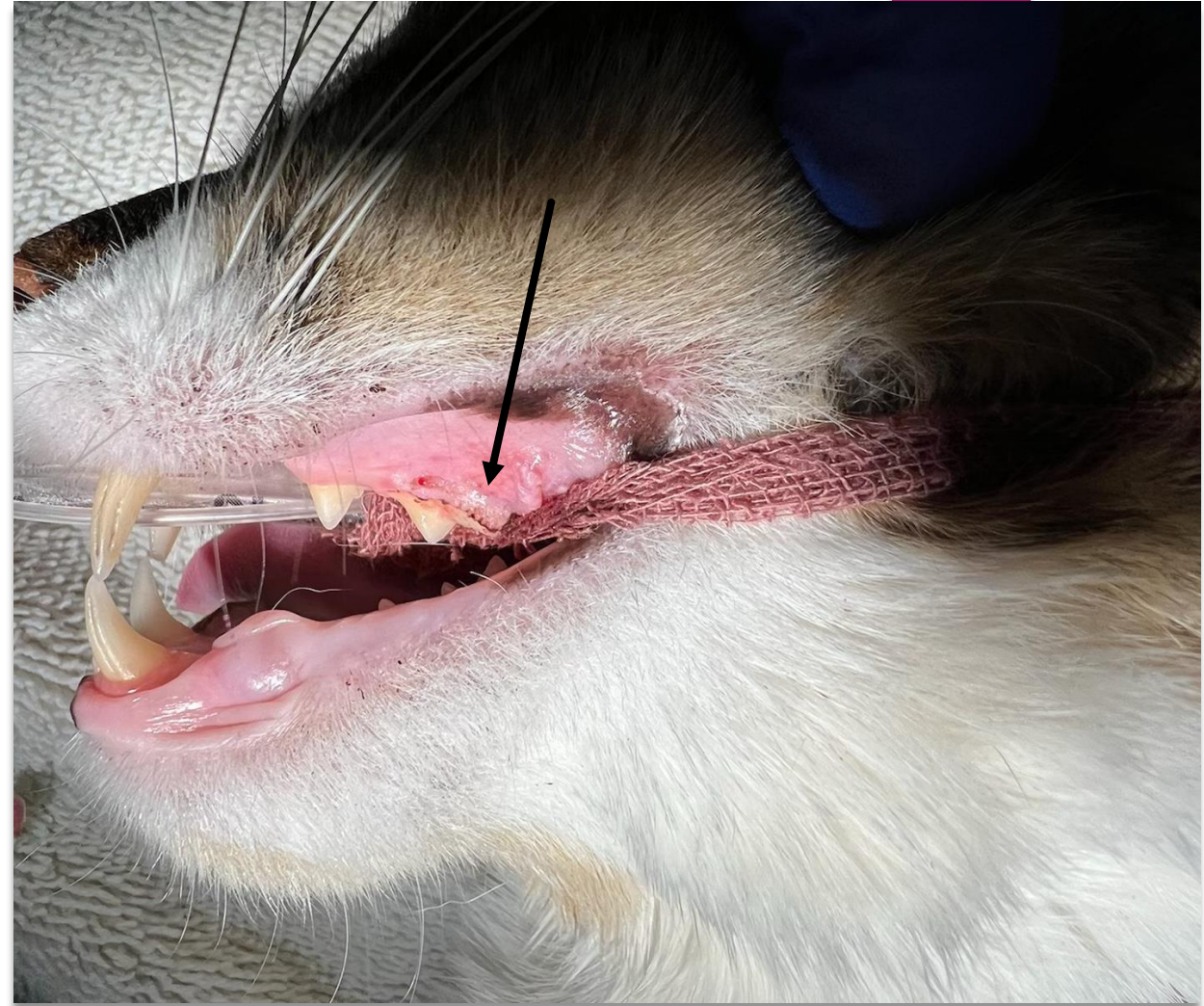- Application of KonKure™ for 10 - 30 seconds after drying the tissues with air or gauze sponge
- Rinsed with saline or water, post application





## MILD FELINE STOMATITIS

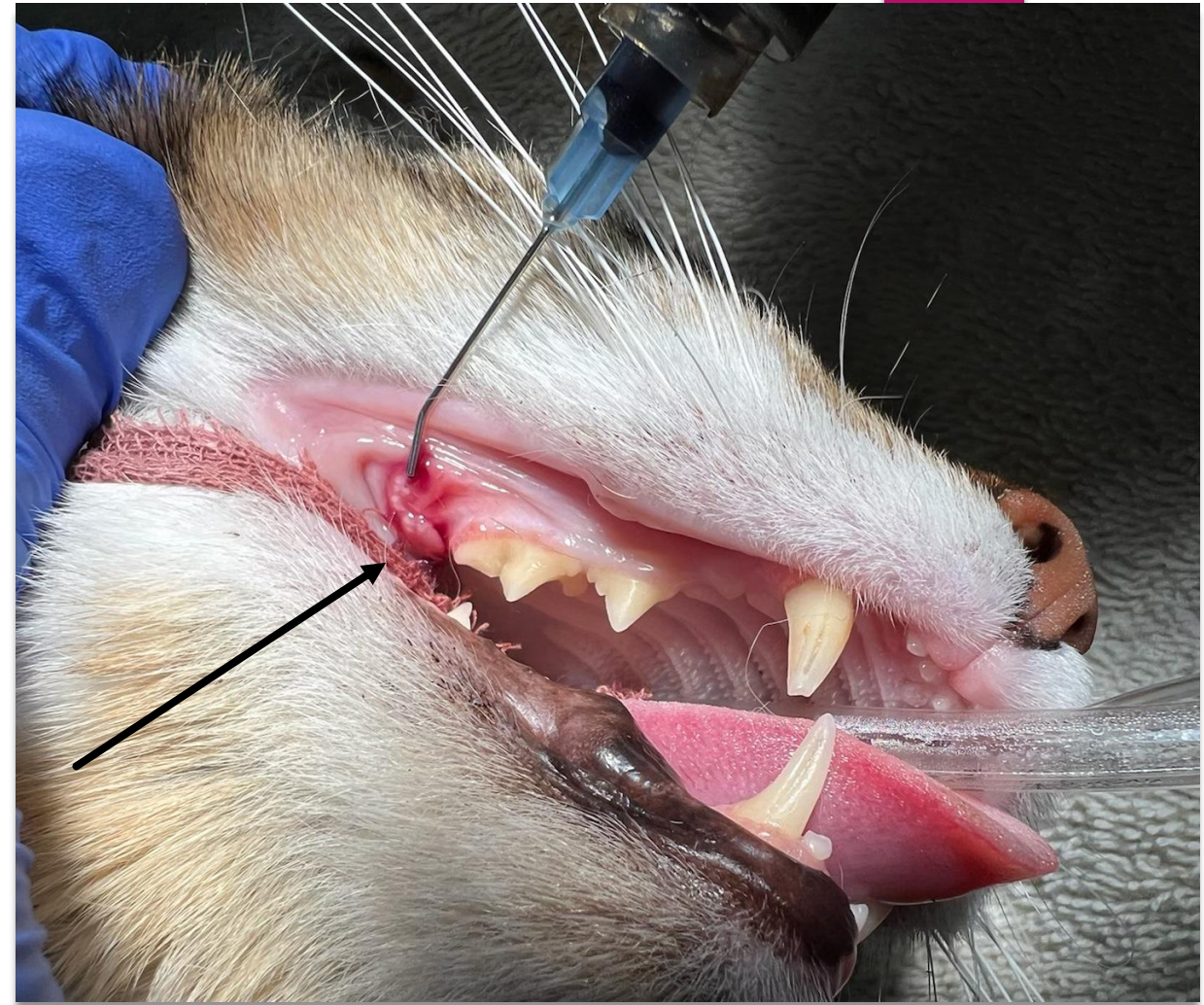
- Post application of KonKure
- Note the whitish to grey color of the tissue.
- This is the coagulum that forms as a result of the process of desiccation
- The coagulum harbors the diseased tissue, bacteria and post inflammatory markers that cause wound chronicity





## MILD FELINE STOMATITIS

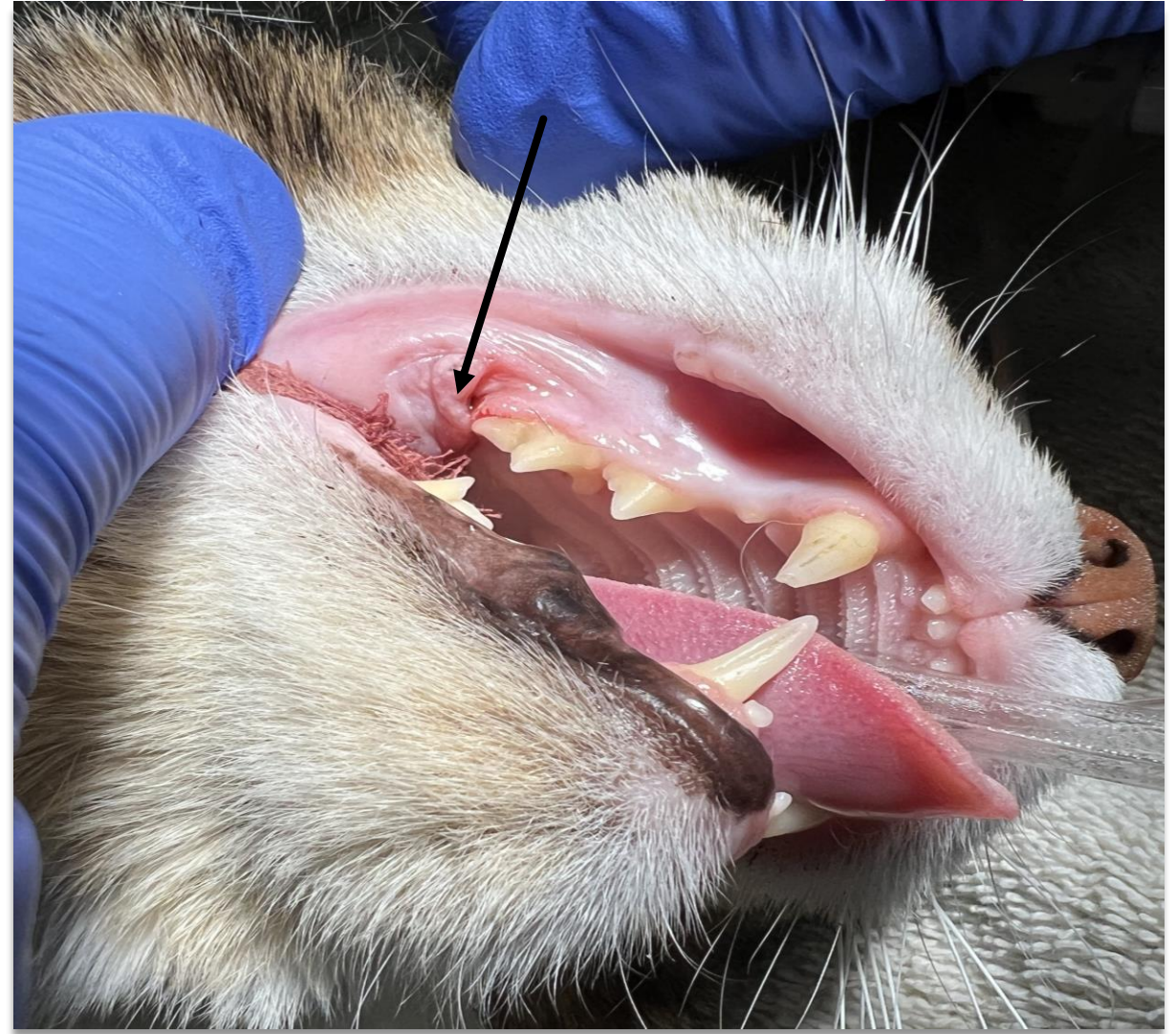- KonKure applied for 10 seconds to right mandibular commissure lesion





## MILD FELINE STOMATITIS

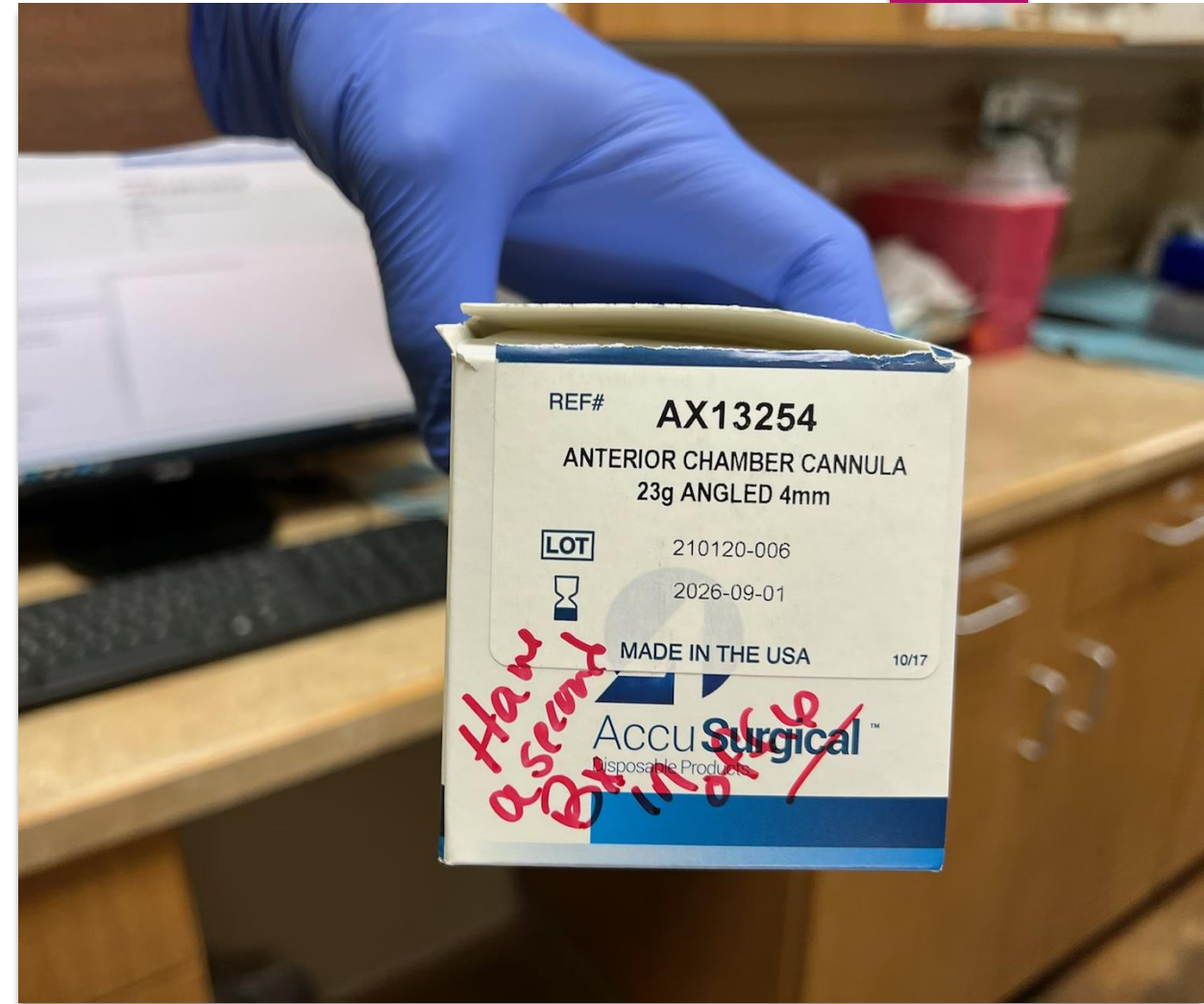
- Post KonKure 10 second application
- Note bilateral chewing gum lesions in commissure of mouth
- Again, coagulum formation via desiccation





## MILD FELINE STOMATIS

- Excellent cannula choice for dispensing KonKure



# SUMMARY

- Biddie is pain free again after his second KonKure treatment in 6 months
- His behavior is improved, he stopped fighting and spraying in the home
- I recommend stomatitis cases be re-examined every 6 months and retreated as clinically indicated
- I have seen total cures of stomatitis with KonKure in my over 10 years of experience with KonKure.

